

# Ureterocystoplasty in a teenage boy: a case report

F Ahmed,<sup>1</sup> PA Dewan<sup>2</sup>

<sup>1</sup> Department of Medicine, Monash University, Australia

<sup>2</sup> Department of Paediatric Urology, Sunshine Private Hospital, Australia

Corresponding author, email: [paddy@paddydewan.com](mailto:paddy@paddydewan.com)

Bladder augmentation may be required for patients with a small, high-pressure bladder and associated incontinence, particularly if related to renal injury. Ureterocystoplasty (UC) using a dilated ureter expands capacity without bowel incorporation risks. We report a teenage boy with spina bifida, an associated neuropathic, high-pressure bladder, and an obstructed, dysplastic left kidney. Via two extraperitoneal incisions, the kidney was removed, and UC was performed. Postoperatively, the patient achieved continence without anticholinergics on intermittent catheterisation. This case highlights the technique's versatility, suitability for older patients, and advantages in avoiding bowel-related complications, reducing the sepsis risk by removing a redundant system, and lowering the hypertension risk through nephrectomy.

**Keywords:** ureterocystoplasty, bladder augmentation, neurogenic bladder, nephrectomy, extraperitoneal

## Case study

Born in India, with spina bifida that was closed soon after birth, our patient came to Australia in 2022. He began intermittent catheterisation with anticholinergic medication. He was 14 years old at the time of the first evaluation for UC consideration. His back was repaired as a baby, his intellectual and bowel functions were normal, and his lower limb movement was only minimally affected by the spinal dysraphism. As part of controlling urosepsis, he had undergone a circumcision to reduce the risk of intermittent catheterisation associated with infection, and he was maintained on oxybutynin. Despite well-managed, intermittent catheterisation, he remained incontinent even with anticholinergic medication, and he had recurrent urine infections despite the circumcision.

A cystogram indicated a moderate bladder size, but with a highly trabeculated bladder and a left-sided paraureteric diverticulum (Figure 1), without vesicoureteral reflux into the left kidney, probably because of the diverticulum. A formal urodynamic study was not undertaken, as the indication for surgery was recurrent urosepsis in the presence of a non-functioning kidney and a thickened, trabeculated bladder.

A mercaptoacetyltriglycine (MAG3) scan showed the left side to contribute only 2.9% of the overall renal function from a small, scarred kidney (Figure 2). With the combined purposes of reducing the infection risk because of the dilated, non-functioning left kidney (shown in Figure 3) and the associated infection, improving his continence, and reducing the risk of developing changes in the right kidney, the patient underwent an extraperitoneal, two-incision UC.

Initially, under general anaesthetic, the patient was placed in the left-up lateral position, and a muscle-cutting incision was used to mobilise and remove the left kidney. Then the proximal end of the ureter was ligated, retaining some of the renal pelvis with the ureter, which had been divided from the excised kidney. The ureter was dissected to the level of the bony pelvis, where it remained until delivered into the subsequent suprapubic wound. The lateral wound was closed, and the patient was repositioned to the supine position.

A skin-crease suprapubic incision was performed, and dissection was carried down to the bladder, which was incised longitudinally in the midline anteriorly, down to just above the bladder neck. The incision extended to the dome of the bladder. From the dome, the bladder incision was elongated to the left ureteric orifice. After being mobilised into the pelvic wound, the ureter was incised longitudinally, and the open ureter was incorporated as a clam UC, using two parallel, continuous sutures to complete the ureter-to-bladder join. A 10 FR Malecot catheter was sutured into the bladder. The patient's recovery was minimally complicated by a left flank haematoma that necessitated transfusion.

In the 18 months after the procedure, the patient became continent without further need of anticholinergic medication, with catheter

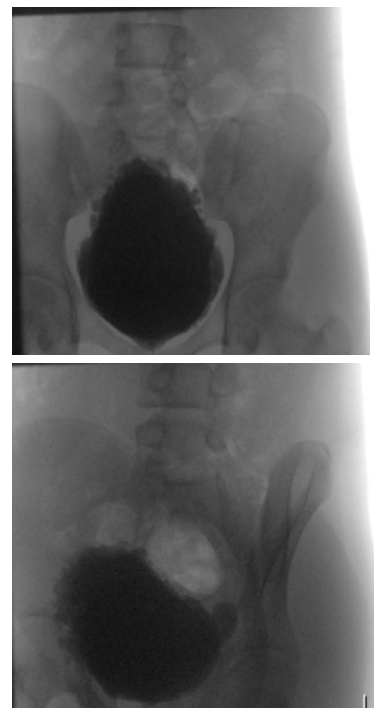


Figure 1: A preoperative cystogram shows marked trabeculation (top) and a left paraureteric diverticulum (bottom), with a bladder volume of 400 ml at 40 cmH<sub>2</sub>O

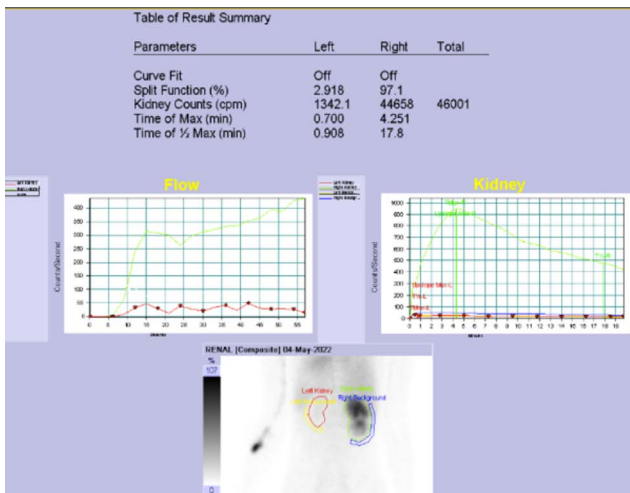


Figure 2: The preoperative MAG3 study shows the overall function of the left kidney to be 2.9%

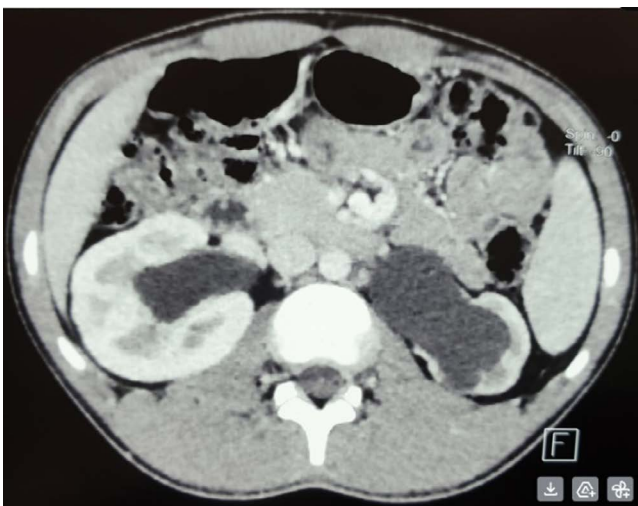


Figure 3: Preoperative computed tomography scan shows significant dilatation of the pelvis, which was also reflected in the findings of the ureter

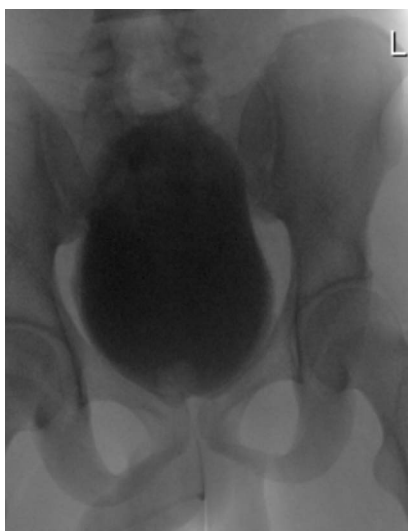

Figure 4: A cystogram, performed 18 months after the augmentation, shows a much smoother bladder that lost the trabeculation, and there was no paraureteric diverticulum

volumes of up to 700 ml. Our urodynamic study showed a total bladder volume of 725 ml at a detrusor pressure of 40 cmH<sub>2</sub>O, 500 ml at 25 cmH<sub>2</sub>O, and 300 ml at 20 cmH<sub>2</sub>O. A repeat radiological

study of the bladder showed that his bladder was no longer trabeculated (Figure 4).

## Discussion

Bladder augmentation is a cornerstone in managing patients with poorly compliant, high-pressure bladders that cause incontinence and progressive renal injury. While enterocystoplasty (EC), which uses bowel segments, usually the ileum, is the traditional approach, the long-term metabolic and urological risks associated with incorporating intestinal lining have prompted consideration of other techniques.<sup>1</sup> UC, which uses a dilated ureter, offers a bowel-free solution that preserves the urothelium and native tissue physiology, thereby avoiding many bowel-related complications, while concurrently reducing the potential infection risk of redundant renal tract tissue.<sup>2</sup> Moreover, it potentially reduces the risks from infection-prone and hypertension-causing dysfunction of urinary tract components.

In our case, UC was selected not only for bladder capacity expansion but also to repurpose a dilated ureter that would otherwise have been discarded. The patient had a severely dysfunctional left kidney and a significantly dilated ureter, making nephrectomy necessary, but also presenting an ideal opportunity for ureteral reuse. The ureter was mobilised and detubularised to create a compliant patch, avoiding the need for bowel tissue and minimising operative complexity.

The effectiveness of UC in improving urological function and bladder dynamics is well documented across several studies. These studies consistently report increased bladder capacity, improved compliance, and decreased detrusor pressures following UC – outcomes that are often comparable to those achieved with traditional EC.<sup>3,4</sup> Özdemir et al.'s<sup>3</sup> retrospective analysis, consisting of 14 patients who underwent UC alongside nephrectomy, demonstrated a significant 318% increase in their mean bladder capacity. At their 12-month follow-up, no uninhibited bladder contractions were detected.<sup>3</sup>

Beyond functional outcomes, UC also avoids the metabolic complications and reduces the risk of urinary tract infections typically associated with EC.<sup>5,6</sup> A single-centre retrospective study comparing UC and EC over 20 years found significantly more frequent occurrences in the development of urosepsis and febrile urinary tract infections in the patient group who underwent EC.<sup>7</sup> Another analysis noted that patients undergoing UC have lower rates of long-term stone formation and metabolic issues compared with those receiving a form of ileocystoplasty.<sup>6</sup> Collectively, these findings support UC as a durable and physiologically better alternative for bladder augmentation in appropriately selected cases.

Beyond standard indications, UC has also been successfully employed in a range of unique contexts, highlighting its adaptability as an augmentation tool. Case reports have demonstrated that UC can be performed following bilateral nephrectomies, utilising both ureters to achieve adequate bladder augmentation – a deviation from the classic scenario of using a dilated ureter from an ipsilateral,

non-functioning kidney.<sup>8</sup> In one such case, a novel “teapot” configuration allowed for efficient incorporation of both ureters into the bladder, providing excellent postoperative bladder capacity and compliance.<sup>8</sup>

UC has also proved feasible in bladder exstrophy in a unique case with an obstructed ureter, in which the dilated right ureter was used to augment the bladder after a transureteroureterostomy.<sup>9</sup> This highlights the adaptability of UC in complex anatomical scenarios, where the otherwise discarded ureteric segments can be repurposed. In this particular case, adjunctive techniques, like transureteroureterostomy, enable optimal utilisation of functional tissue by repurposing ureteric tissue while preserving the ipsilateral kidney when it is still functional. This approach has also been successful in other cases.<sup>10</sup>

Currently, if there is no megaureter, it is not possible to perform a UC, which is a limitation of this procedure. Results of animal studies show that a normal-calibre ureter can be dilated sufficiently to augment the bladder within a short period (unpublished data from our laboratory). In a rabbit model, the investigators obtained sufficient ureteral dilatation to perform a bladder augmentation within 30 days after dilatation with daily saline injections. They reported a 260% average increase (190–380%) in bladder capacity 3–6 months after the surgery.<sup>11</sup> Clinical studies generally agree that the ureter should be 1 cm to survive and augment the bladder, noting that this can be with a short length, as shown in a child with a single kidney.<sup>10</sup> However, others, including Husman et al.,<sup>12</sup> suggest that the ureter needs to be at least 1.5 cm in diameter. We regard the value as not being absolute.

Taken together, these findings support UC as a safe, effective, and adaptable alternative to traditional EC. Our experience, supported by a broader cohort of 44 UC cases performed across multiple countries through the Kind Cuts for Kids organisation, demonstrates both the reproducibility and scalability of this technique. In that group, 23 had an extraperitoneal ureteroureterostomy, 11 had a transperitoneal ureteroureterostomy, seven had an extraperitoneal nephrectomy, and three had other procedures due to individual complexities. Of these patients, 28 were male, 14 of whom had congenital urethral obstruction; most of the remainder had a neuropathic bladder. Those at follow-up had their bladder volume improve from 73 ml to 263 ml on average.

## Conclusion

As surgical practices move toward tissue-preserving, physiologically suitable techniques, UC has the potential to become more widely used in bladder augmentation and deserves recognition and adoption. However, preserving the blood supply during dissection requires a high level of technical skill.

## Conflict of interest

The authors declare no conflict of interest.

## Funding source

No funding source to be declared.

## ORCID

F Ahmed  <https://orcid.org/0009-0006-0753-0057>

PA Dewan  <https://orcid.org/0000-0003-2808-7921>

## References

1. Mehmood S, Alhazmi H, Al-Shayie M, et al. Long-term outcomes of augmentation cystoplasty in a pediatric population with refractory bladder dysfunction: a 12-year follow-up experience at a single center. *Int Neurourol J*. 2018;22(4):287-94. <https://doi.org/10.5213/inj.1836174.087>.
2. Dewan PA, Nicholls EA, Goh DW. Ureterocystoplasty: an extraperitoneal, urothelial bladder augmentation technique. *Eur Urol*. 1994;26(1):85-9. <https://doi.org/10.1159/000475348>.
3. Özdemir T, Arkan A. Ureterocystoplasty in pediatric patients with unilateral nonfunctioning kidney. *Turk J Urol*. 2013;39(4):232-6.
4. Nahas WC, Lucon M, Mazzucchi E, et al. Clinical and urodynamic evaluation after ureterocystoplasty and kidney transplantation. *J Urol*. 2004;171(4):1428-31. <https://doi.org/10.1097/01.ju.0000118761.88563.70>.
5. Landau EH, Jayanthi VR, Khoury AE, et al. Bladder augmentation: ureterocystoplasty versus ileocystoplasty. *J Urol*. 1994;152(2 Pt 2):716-9. [https://doi.org/10.1016/S0022-5347\(17\)32689-7](https://doi.org/10.1016/S0022-5347(17)32689-7).
6. Parkinson E, Robb A, McCarthy L. Long-term survival of bladder augmentation is influenced by its shape and mucosal lining. *J Pediatr Surg*. 2025;60(3):162051. <https://doi.org/10.1016/j.jpedsurg.2024.162051>.
7. Zafarghandi RM, Zeraati A, Tavakoli M, Moghaddam FK, Zafarghandi MM. Comparison of enterocystoplasty and ureterocystoplasty before kidney transplantation. *Int J Organ Transplant Med*. 2010;1(4):177-82.
8. Nativ O, Livne P, Zu'bi F, et al. Simultaneous renal transplantation with bilateral nephrectomy and ureterocystoplasty. *Urology*. 2023;173:164-7. <https://doi.org/10.1016/j.urology.2022.11.018>.
9. Dewan PA, Erdendsetseg G, Zhao ZG, Anderson P. Ureterocystoplasty as part of primary closure of bladder exstrophy. *BJU Int*. 2003;92(1):146-9. <https://doi.org/10.1046/j.1464-410X.2003.04286.x>.
10. Dewan PA, Condron SK. Extraperitoneal ureterocystoplasty with transureteroureterostomy. *Urology*. 1999;53(3):634-6. [https://doi.org/10.1016/S0090-4295\(98\)00363-X](https://doi.org/10.1016/S0090-4295(98)00363-X).
11. Lailas NG, Cilento B, Atala A. Progressive ureteral dilation for subsequent ureterocystoplasty. *J Urol*. 1996;156(3):1151-3. [https://doi.org/10.1016/S0022-5347\(01\)65740-9](https://doi.org/10.1016/S0022-5347(01)65740-9).
12. Husmann DA, Snodgrass WT, Koyle MA, et al. Ureterocystoplasty: indications for a successful augmentation. *J Urol*. 2004;171(1):376-80. <https://doi.org/10.1097/01.ju.0000100800.69333.4d>